

Autism, Asthma, Irritable Bowel Syndrome, Strabismus, and Illness Susceptibility: A Case Study in Chiropractic Management.

William C. Amalu, DC, DABCT, DIACT, FIACT

ABSTRACT

Pathologies of organic origin are commonly thought to be the exclusive realm of medical treatment and not part of the mainstay of chiropractic care. The clinical observations of a patient presenting with autism, asthma, irritable bowel syndrome, strabismus, and illness susceptibility are reported. Alleviation of symptoms is seen subsequent to corrections of abnormal biomechanical function of the occipito-atlanto-axial complex. A relationship between biomechanical faults in the upper cervical spine and the manifestation of abnormal central neurophysiological processing is suggested as the genesis of this patient's symptomatology.

Key words: Autism, Asthma, IBS, Strabismus, Infrared Imaging, Upper Cervical Spine.

INTRODUCTION

Autism usually manifests itself in the first year of life with onset rarely later than 30 months of age. The cause of autism is unknown, but evidence points to a neurological basis. The syndrome is characterized by extreme aloneness (lack of attachment, failure to cuddle, and avoidance of eye contact); insistence on sameness (resistance to change, ritual morbid attachment to familiar objects, and repetitive acts); disordered speech and language (which varies from total muteness to markedly idiosyncratic use of language); and uneven intellectual performance. The syndrome tends to maintain a consistent symptomatic picture throughout development.

Medical treatment, for the most severely impaired children, includes systematic application of behavior therapy; a technique that can be taught to parents in order to help manage the child in the home and at school. The benefits of this therapy vary widely, but may be considerable for these children who try the patience of the most loving parents and devoted teachers. Medications provide limited benefit and are used mainly in controlling the most severe forms of aggressive and self-destructive behavior. However, they do not resolve the condition (1-3).

Asthma is a lung disease characterized by: airway obstruction that is reversible (but not completely in some patients), airway inflammation, and increased airway responsiveness to a

variety of stimuli. The airway obstruction in asthma is due to a combination of factors that include: smooth muscle spasm of the airways, edema of the airway mucosa, increased mucus secretion, cellular infiltration of the airway walls, and injury and desquamation of the airway epithelium. A family history of allergy or asthma can be elicited in most asthmatics.

Research on the pathophysiology of asthma over the past decade has focused on the inflammatory cells and their mediators, neurogenic mechanisms, and vascular abnormalities involved. Recent interest in neurogenic mechanisms has focused on neuropeptides released from sensory nerves by an axon reflex pathway. These peptides have vascular permeability and mucus secretagogue activity, bronchoconstrictor activity, and a bronchial vascular dilation effect. These sensory nerves also act on the pulmonary airways and their microvasculature contributing to the special kind of airway inflammation that is characteristic of asthma.

The medical treatment of asthma may be conveniently considered as management of the acute attack and day-to-day therapy. Drug therapy focuses on the two main aspects of the disease: bronchospasm and inflammation. Sympathomimetic medications cause bronchial smooth muscle relaxation as their effects mimic those of the sympathetic nervous system. The inflammatory aspect is managed with corticosteroids. While systemic corticosteroids are considered exceptionally effective, they are reserved for more difficult episodes because of their potential for serious adverse effects (1-3).

Irritable bowel syndrome (IBS) is characterized as a motility disorder involving the entire hollow GI tract, creating an upper and lower GI symptom complex. The etiology of IBS is unknown. No anatomic cause can be found. Two major groups or clinical types of IBS are recognized. In the spastic colon type, most patients have pain over one or more areas of the colon associated with periodic constipation or diarrhea. The second group of IBS patients primarily manifest painless diarrhea, usually urgent, precipitous diarrhea that occurs immediately upon rising or, more typically, during or immediately after a meal.

The pathophysiology of IBS is based upon motor abnormalities of both the small and large bowel. When the normal segmentation mechanism of the sigmoid colon becomes hyperreactive, so-called spastic constipation results. In contrast, diminished motor function is found in the group associated with diarrheal episodes. Treatment is basically supportive and palliative. If offending foods can be identified, diet changes are suggested. Medical management with drugs are used only as a temporary expedient to relieve spastic pain (1-3).

Strabismus is characterized as the deviation of one eye from parallelism with the other. The etiology is either paralytic or myospasmodic. Paralytic (nonconcomitant) strabismus results from paralysis of one or more ocular muscles and may be caused by a specific oculomotor nerve lesion. Nonparalytic (concomitant) strabismus usually results from unequal ocular muscle tone caused by a supranuclear abnormality within the CNS. A concomitant strabismus may be convergent (esotropia), divergent (exotropia), or vertical (hyper- or hypotropia).

The focus of medical treatment is for muscle imbalance. If this alone is responsible, strabismus is treated early with corrective glasses or contact lenses, medications, orthoptic training (eg. eye exercises, patching the normal eye, etc.), or surgical restoration of the muscle

balance. Permanent loss of vision can occur if strabismus and its attendant amblyopia are not treated before the age of 4 to 6 yrs., with intermittent follow-up examinations at least until age 10 (1-3).

Considering the above pathophysiology and treatment approach to this patient's conditions, it can be understood that the contribution of chiropractic care in the management of these diseases is considered to be of no significance to the medical community. However, the body of literature detailing a possible upper cervical etiology, or at least contribution, is substantial; and the case made for greater recognition of the involvement of abnormal upper cervical spine biomechanics is compelling.

CASE REPORT

A 5 year old female was referred to our clinic with the chief complaint of autism. Her parents advised that the patient had also been diagnosed with asthma, allergies, irritable bowel syndrome, and left sided strabismus. The patient's diagnosis was made through an extensive medical workup at a specialized autism research institute with the other conditions diagnosed over time by various medical specialists.

Her mother reported that she had been very susceptible to illnesses since birth, but had experienced normal development until a viral upper respiratory illness at 21 months of age. The URI developed into a complication with asthma necessitating a 5 day regimen of prednisone. The patient's mother advised that she was never the same and began to deteriorate from that point on.

At the time of consultation, the patient had been experiencing 25 violent temper episodes per day with each episode lasting up to 20 minutes. The episodes consisted of ear piercing screams, combatant behavior, and the patient throwing herself onto the floor. She also exhibited 3 episodes each day of self-inflicted violent behavior which included biting her arm, slapping her head, and repeatedly banging her head against a full length mirror. Her parents advised that she also expressed at least 1 episode each day of outward violent behavior which consisted of hitting people, especially her mother to include slapping the glasses off her face.

The patient's speech was limited to only a few words such as mama, dada, milk, and walk. Her fine motor skills were delayed to the extent that she could only feed herself with her fingers. The patient's sleep pattern was considerably disturbed with waking screaming at least twice at night and once with napping. It was also very difficult to get her back to sleep once this occurred. The most difficult time was trying to get the patient to sleep in the evening. Every night consisted of 1-1 1/2 hours of screaming, comforting, and stories just to get her to sleep.

The irritable bowel syndrome was described by her parents as profuse loose bowel movements which would occur 4 times a day with the need to change clothes. They were unable to correlate any food sensitivities or pattern to the bowel movements. Due to her overall condition she was unable to be toilet trained. Her parents also noted that she was allergic to

dust and plastics. She had constant eczema behind each ear along with rashes, redness, and sores which could appear at random anywhere on her body.

Her parents noted that she had continued to be very susceptible to illnesses. Out of 8-10 months per year, the patient would experience a URI or flu lasting at least 3 weeks each time. Of these illnesses, 50% would include asthma attacks necessitating the use of albuterol or a 5 day regimen of prednisone. Occasionally, she would have to be taken for in-office nebulizer treatment.

At the time the patient was seen in our clinic, she had been undergoing various forms of home behavior therapies along with attempted eye patching with limited results. Her parent's noted that most of her symptoms were getting worse in both intensity and frequency.

Upon examination, the patient presented in constant motion with running on her toes while loosely flapping her hands and arms. Her gait included a bilateral toe-in with a marked increase on the right. She was uncommunicative, uncooperative, and prone to screaming violent outbursts. Vital signs, ear, nose, and throat examinations were unremarkable with the exception of bilateral posterior auricular eczema.

Orthopedic examination revealed significant palpatory hypertonicity of the paraspinal musculature from the occiput to C3 bilaterally with a marked increase on the right. A combination of screaming, arched cervical extension, and outward violence suggested tenderness in the same areas. The patient demonstrated a reduction in passive cervical extension and right lateral flexion. Her lumbosacral evaluation was unremarkable.

Gross neurologic examination was also found to be unremarkable. A moderate left esotropia was noted along with a mild right. A paraspinal digital infrared imaging analysis was performed in accordance with thermographic protocol (4-6). Due to the patient's violent behavior, she had to be restrained by both parents and the doctor in order to take the scan. A continuous paraspinal scan consisting of approximately 300 infrared samples was taken from the level of S1 to the occiput.

The data was analyzed against established normal values and found to contain wide thermal asymmetries indicating abnormal autonomic regulation or neuropathophysiology (7-10) (Figs. 1 and 2).

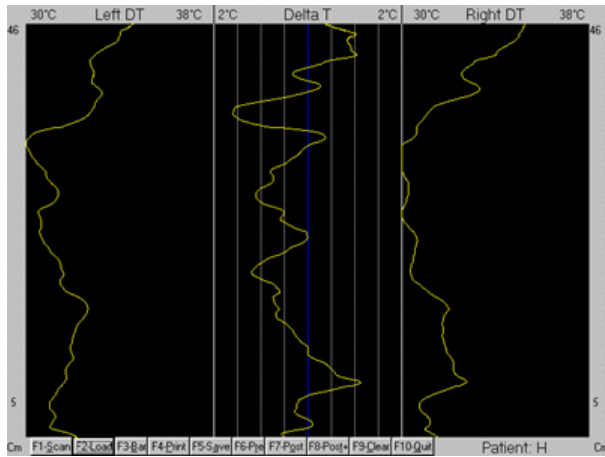


Figure 1

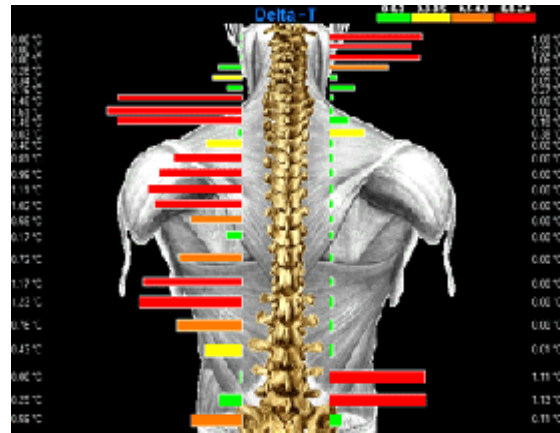

Figure 2

Since the cervical spine displayed highly abnormal thermal asymmetries, a focused scan was performed with approximately 75 infrared samples taken from T1 to the occiput (Figs. 3 and 4).

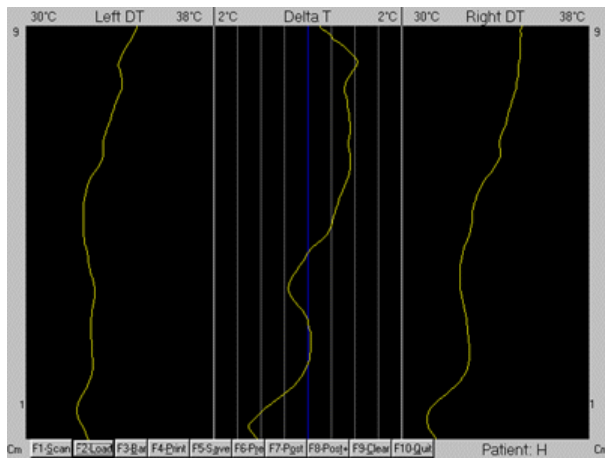


Figure 3

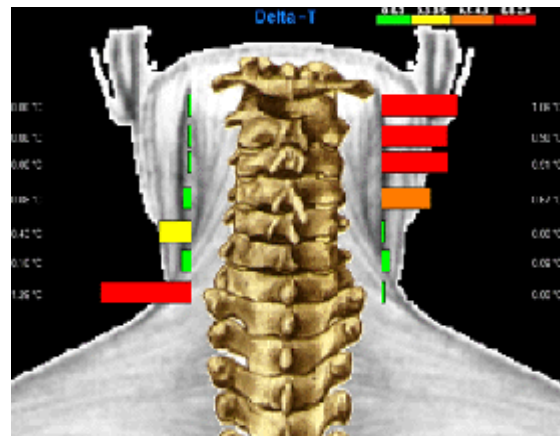

Figure 4

The full spine scans also displayed an abnormal central hypothermia of the spine, which suggests long standing nervous system dysfunction (Figs. 1 and 5).

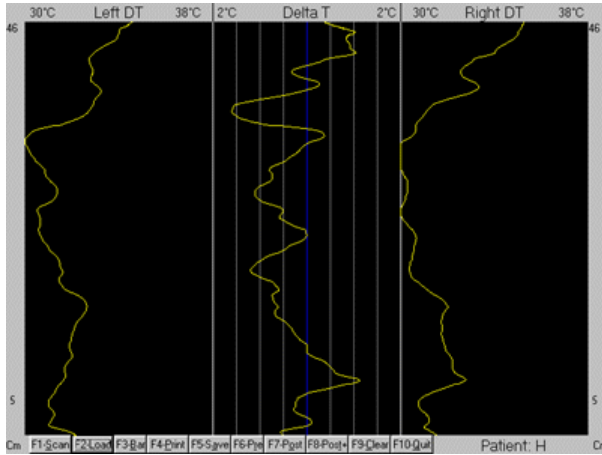


Figure 1

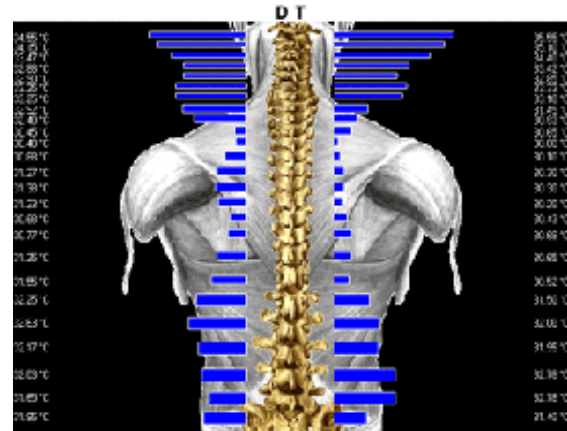


Figure 5

The above information yielded a high suspicion of abnormal upper cervical arthrokinematics. Consequently, a precision upper cervical radiographic series was performed for an accurate analysis of specific segmental biomechanics (11). Since positioning chairs and head clamps cannot be used with infants or uncooperative children, supine table films were taken using an on-patient laser-optic alignment system to precisely align the patient to the central ray. With this system, maintenance of precision patient alignment can be facilitated without a head clamp system due to the laser being aligned to the source of the X-ray beam rather than the bucky. However, with children who are old enough to sit on their own, weight-bearing laser-optic alignment is preferred (Figs. 6 and 7).



Figure 6

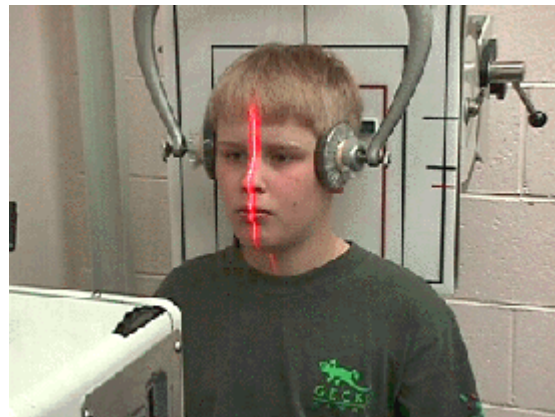


Figure 7

An analytical radiographic method consisting of mensuration combined with arthrokinematics was performed (11). Biomechanical abnormalities were noted at the atlanto-occipital and atlanto-axial articulations.

CHIROPRACTIC MANAGEMENT

Correction of the atlanto-occipital subluxation was chosen as the first to be adjusted from the accumulated degree of aberrant biomechanics noted at this level. Before treatment was rendered, the parents were counseled that they may expect exacerbations in symptomatology as part of the normal response to care due to the global impact of neural reintegration.

To correct the subluxation, the patient was placed on a specially designed knee-chest table with the posterior arch of atlas as the contact point. An adjusting force was introduced using a specialized upper cervical adjusting procedure (12). The patient was then placed in a post-adjustment recuperation suite for 15 minutes as per thermographic protocol (4-6). Correction of the subluxation was determined from the post-adjustment cervical infrared scan noting resolution of the patient's presenting neuropathophysiology (Figs. 8 and 9).

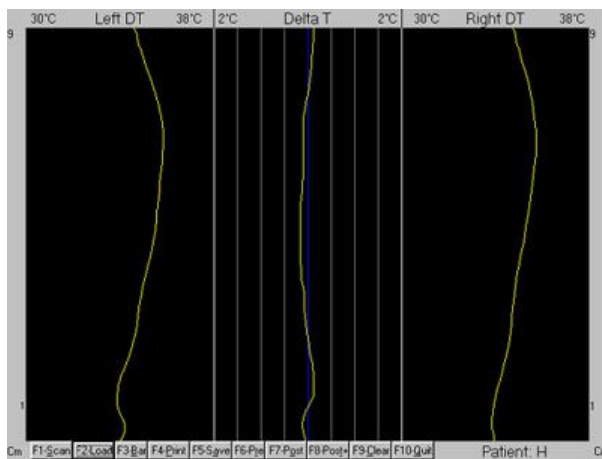


Figure 8

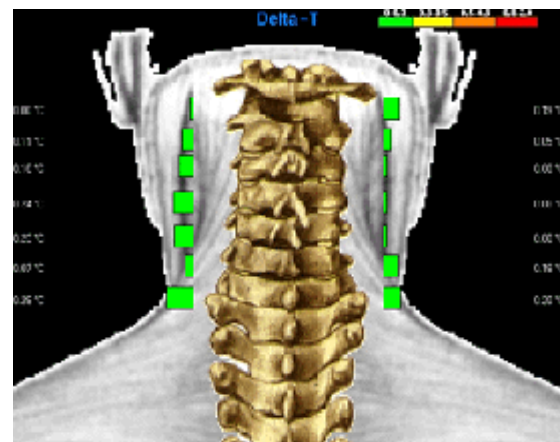

Figure 9

All subsequent office visits included an initial cervical infrared scan; and if care was rendered, another scan was performed to determine if normal neurophysiology was restored. Since the focus of the patient's care was in the upper cervical spine, infrared scans were made in this region only during normal treatment visits with full spine scans performed at 30-day re-evaluation intervals.

The patient was adjusted twice during the first week of care. After the first adjustment, the patient's mother noted that she had her first good night sleep since she could remember. By the end of the week, she reported that the patient's violent temper episodes had reduced to 15 per day along with a substantial decreased in intensity. She noted that reasoning with the patient could stop them now. The patient's self-inflicted violent behavior was also decreasing in frequency. Her speech had suddenly improved with an increase in vocabulary with the ability to expressing feelings (saying hungry, tired, mad). Her sleep pattern also changed to waking only once at night along with longer napping times. The patient's mother reported that she was running less and walking more flat footed. Performing thermal scans had also become much easier as she was now able to sit on her own without restraint.

During the second week of care the patient was adjusted only once. Her mother reported that by the end of the week the temper episodes had decreased to only 5 per day with a further decrease in intensity. She also noted that she was able to stop them quickly. The patient's left strabismus had improved to the point that her mother noticed it only twice since the week before. She advised that the right eye showed no signs of strabismus since treatment began. The patient's mother was elated to report that she had been increasingly vocal this week and began speaking in sentences for the first time. She was also able to nap now without waking and woke only once per night this week with the ability to go back to sleep on her own. Her toe in gait continued to decrease with more flat-footed walking. Her mother reported a marked decrease in hyperactivity along with wanting to be touched and hugged now.

The patient was adjusted once during the third week of care. By the end of the week, the patient's violent temper episodes had decreased to only twice per day with a continued decrease in intensity. Her mother noted that she continued to speak using more sentences and vocalizing disappointment, anger, hunger, tiredness, and other feelings. The patient's strabismus was now showing up in the left eye only when tired. Her gait was absent of toe-in by this time. Her mother advised that there was very little running or hyperactivity now. She had also ceased to display any self or outward violent behavior. The patient's mother also noted that her IBS had improved to the point of 1-2 loose bowel movements per day with only an occasional need to change clothes. She noted that the patient was now beginning to recognize bowel and bladder functions on her own. Because she was doing so well, they decided to go to a friend's house as a family for the first time. The patient's social behavior was excellent; she played with their dog, used the stairs without falling, and came home and asked to go to bed because she was tired.

No adjustments were necessary during the fourth week of care. The patient's mother reported that by the end of this week all temper episodes, hyperactivity, self and outward violent behavior had stopped. She was now napping and sleeping through the night perfectly. The patient was also walking more and more, running less, and showed no signs of toe-in. Her mother advised that there were no signs of any strabismus by this time. The IBS continued to improve with only one loose bowel movement per day at the most and only a rare clothing change. Her mother also noted that the eczema behind her ears had cleared up and that her allergic skin reactions had stopped.

Before entering our clinic for care, an appointment had been made at a special autism, occupational therapy, and speech center to evaluate the patient for specialized therapy. Her parents decided to keep the appointment due to the difficulty in getting one in the first place and to see what if anything could further the patient's development. The patient underwent one hour of observation and evaluation by two therapists. Upon conferring their findings they both reported that the patient did not have autism and that there must have been a misdiagnosis. The patient's mother was pleasantly amused and elated by this and proceeded to explain in detail the patient's behavior four weeks previously. Upon hearing this, the therapists agreed that the original diagnosis was autism, but that the patient was not currently exhibiting this disorder. They reported that due to her current level of behavior that she would not need in-center therapy and that they would give the parents work for her to do at home. Their report also noted that at her current rate of improvement she would be able to function in society.

A re-evaluation was also performed in our center at this time. The examination revealed: no signs of posterior auricular eczema, normal cervical muscle tone, cervical PROMs WNL, lack of toe-in gait, and bilateral central positioning of the eyes. A full spine paraspinous infrared scan was performed at this time noting near total resolution of the patient's presenting neuropathophysiology along with a return of normal central spinal heat (Figs. 10, 11, and 12).

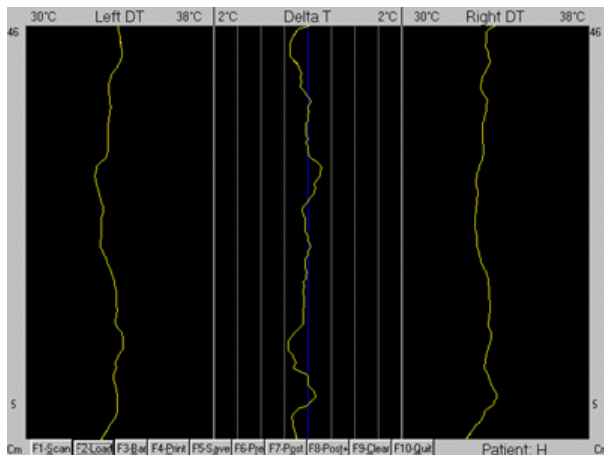


Figure 10

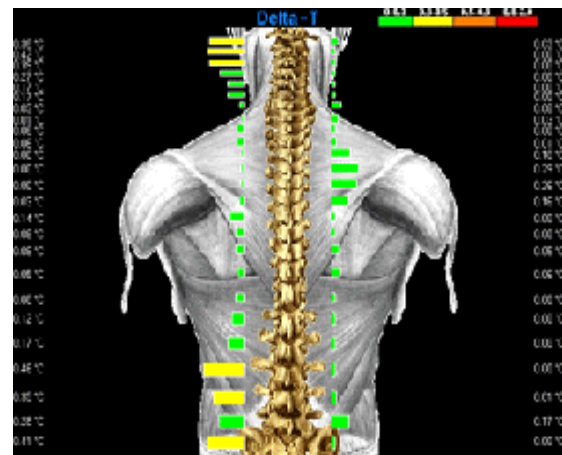


Figure 11

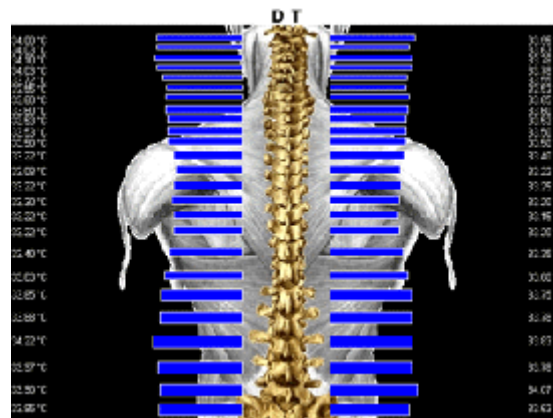


Figure 12

Having the patient in the office had become a pleasure by now. She would hold my hand while walking down the hall, position herself with her back to the examining chair while allowing me to lift her up to sit, and finally holding her own hair out of the way for me to perform an infrared scan.

Weeks six and eight were punctuated by a mild return of symptoms. The patient's mother advised that the temper episodes had returned at approximately once per day along with her left strabismus, but that both were very mild in intensity. Concomitantly, her infrared scans noted a return of her presenting neuropathophysiology necessitating an adjustment once during each week. All of her other conditions continued to improve at a steady rate. Her mother

reported that she was climbing, exploring, and doing things she would never do before. A re-examination was performed at eight weeks with no remarkable findings.

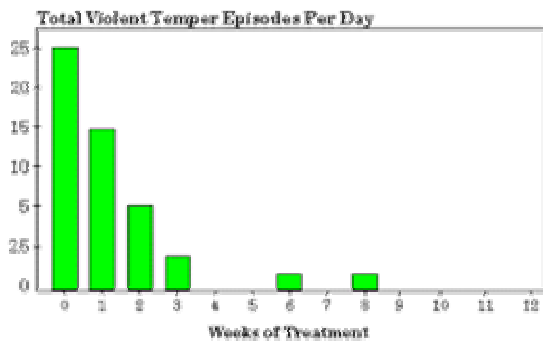


Figure 13

No adjustments were needed during the ninth through twelfth weeks of care. The patient's mother continued to report improvements with no temper episodes, self or outward violent behavior, or strabismus (Fig. 13). Her sleeping habits remained undisturbed. The patient's hyperactivity continued to decrease along with an increased frequency of a heel-toe gait. Her speech continued to improve with more and more sentence use. The IBS had almost completely resolved with no episodes needing a change of clothes.

The patient continued to improve over the next 8 months. Adjustments were rendered very infrequently. Her mother reports that the patient currently exhibits the type of anger in intensity and frequency that normal children have when not getting their way, etc. The patient may rarely show some self-violent behavior with slapping her own head if she is over stimulated or very tired. Any outward violent behavior, if ever seen, is described by her mother as usual childhood behavior as when mad with a sibling. Her sleep pattern continues to be undisturbed. She continues to improve in her speech development with increased use of complex structured sentences. Her gross motor skills have improved to the point of performing somersaults and playing catch, while her fine motor skills include work with holding pencils correctly, using keys, and the ability to feed herself (even soup) using utensils.

Her IBS has almost completely resolved with possibly one loose bowel movement a week with no clothing changes. To her mother's delight she is now toilet training. Her left strabismus is a rare occurrence, hardly noticeable, and only when she is extremely tired. The patient's mother reports that her allergies and eczema never returned. She has also never had another asthma attack. Over the past eleven months of care, the patient has experienced only three minor colds lasting at the most five days. Considering the amount of developmental delay, learning disabilities, and immune dysfunction seen in this patient, it is amazing how much progress she made in such a short amount of time. However, even though improvements continue day-by-day, she still has a long way to go.

NEUROBIOLOGICAL MECHANISMS

There are two extensively studied neurophysiological mechanisms which may explain the profound changes seen in this patient. The first is CNS facilitation (13-17). This condition arises from an initiating trauma (birth, falling, etc.) which causes entrapment of intra-articular meniscoids resulting in segmental hypomobility and finally compensatory hypermobility.

Consequently, hyperexcitation of intra and periarticular mechanoreceptors and nociceptors occurs. Over time, this bombardment of the central nervous system can cause facilitation. Facilitation results in an exponential rise in afferent signals to the cord and/or brain. This may cause a loss of central neural integration due to direct excitation, or a lack of normal inhibition, of pathways or nuclei at the level of the cord, brainstem, and/or higher brain centers. The upper cervical spine is uniquely suited to this condition as it possesses inherently poor biomechanical stability along with the greatest concentration of spinal mechanoreceptors.

The second mechanism is cerebral penumbra or brain cell hibernation (18-24). Previous research held that the neuron had two basic states of existence: function and dysfunction. However, a third state was uncovered which may explain the rapid and profound changes seen in some cases. When a certain threshold of ischemia is reached, the neuronal state of hibernation occurs; the cell remains alive, but ceases to perform its designated purpose. Entire functional areas of the cerebral cortex or cerebellum may be affected. The mechanism of hyperafferency, as mentioned above, plays an initiating role. Hyperafferent activation of the central regulating center for sympathetic function in the brain may cause differing levels of cerebral ischemia. A second route via the superior cervical sympathetic ganglia, may also cause higher center ischemia.

These recent advances in neurophysiological research correlate well with the pathophysiology currently proposed in the presented conditions (1-3). Normalization of frontal lobe and limbic system physiology would account for this patient's drastic personality and behavior changes (1-3). Cerebral penumbra may hold the greatest explanation for the changes seen in autism with specialized upper cervical chiropractic care.

Since recent research has elucidated neurogenic mechanisms which cause bronchoconstriction, mucus secretion, and airway inflammation in asthmatics (1-3), normalization of neural function could correct the condition. In the treatment of asthma, sympathomimetic drugs are used to mimic the normal activity of the sympathetic system (1-3). Why not return function to this system rather than prescribing drugs that mimic it. Normalization of pathological central sympathetic regulation due to cerebral penumbra, and/or direct pathophysiological spinal pathway integration to the bronchial tree, may explain our effects.

In the case of strabismus, supranuclear abnormalities within the CNS or direct oculomotor nerve dysfunction can cause unequal ocular muscle tone (1-3). Correction of cerebral penumbra and/or facilitated pathways could explain the return of normal central ocular positioning in this patient.

Motor nerve abnormalities which cause the bowel motility dysfunction seen in irritable bowel syndrome (1-3), may arise from either pathologies of central motor regulation due to cerebral penumbra or loss of direct pathway controls. Normalization of motor nerve function would cause a return of regular bowel motility.

The role that the sympathetic nervous system plays in the regulation of immune function is substantial (1-3). Dysregulation of this system can result in sympathetically mediated immune

dysfunction and thus, susceptibility to illnesses. Correction of pathological central sympathetic regulation resulting from cerebral penumbra and/or facilitation would lead to a return of normal immune function.

CONCLUSION

The most important factor in this case was our ability to objectively monitor the adjustment's affects on the patient's neurophysiology. Many different types of tests are used in our profession such as leg length, cervical challenge, motion and static palpation, and others. However, these tests lack objectivity, possess inherent errors, and have no literature confirmation of their ability to monitor neurophysiology (25-28). Digital infrared imaging, however, has been researched for over 30 years compiling almost 9,000 peer-reviewed and indexed articles confirming its use as an objective measure of neurophysiology. By using this technology, our clinic has been able to consistently determine the correct adjustive procedures that produce reproducible and dramatic positive neurophysiological improvements in our patients.

If the foundation of our profession stands on the principle that homeostasis is dependent upon coordinated neurophysiology, then we must directly and objectively monitor this system as an outcome measure to our care. But not any way of monitoring this system will suffice. We need to measure the autonomic nervous system if we are to monitor the global systemic aspect of the nervous system's control. Paraspinal digital infrared imaging fulfills this need by objectively measuring the autonomic changes of all 32 spinal nerves as they exit to effect deep visceral function. Since testing does not involve patient compliance, such as movement or a verbal response, paraspinal infrared imaging becomes as objective a test of neurophysiology as we can get.

To what magnitude the upper cervical spine is involved in the genesis of organic conditions remains to be seen. In an atmosphere where much of the public see our profession as useful for neck and back pain treatment at most, patients with complex disorders are left unaware of the possible benefits of care. The body of literature detailing a possible upper cervical etiology, or at least contribution, to organic disorders is substantial. Further research into this area of the spine, combined with objective monitoring of neurophysiology, may reveal that chiropractic does indeed offer consistent conservative management of complex visceral disorders.

ACKNOWLEDGMENTS

The authors would like to gratefully acknowledge the Titronics Research and Development Company. For without their design of the TyTron C-3000 Paraspinal Digital Infrared Scanner, we would not have been able to monitor this patient's neurophysiology.

REFERENCES

- 1.) Schroeder, S., Krupp, M., Tierney, L. *Current Medical Diagnosis and Treatment*. Norwalk, CT: Appleton & Lang; 1988.
- 2.) Berkow, R., Beers, M., et al. *Manual of Diagnosis and Therapy*. Merk & Co.; 16th ed. 1992.
- 3.) Andreoli, T., Carpenter, C., Plum, F. *Essentials of Medicine*. 2nd ed. Philadelphia: W.B. Saunders; 1990.
- 4.) Thermography Protocols - *International Thermographic Society* 1997.
- 5.) Thermography Protocols - *American Academy of Thermology* 1984.
- 6.) Thermography Protocols - *American Academy of Medical Infrared Imaging* 1997.
- 7.) Uematsu, S., Edwin, D., et al. *Quantification of Thermal Asymmetry. Part 1: Normal Values and Reproducibility*. *J Neurosurg* 1988;69:552-555.
- 8.) Feldman, F., Nickoloff, E. *Normal Thermographic Standards in the Cervical Spine and Upper Extremities*. *Skeletal Radiol* 1984;12:235-249.
- 9.) Clark RP. *Human Skin Temperature and its Relevance in Physiology and Clinical Assessment*. In: Francis E, Ring J, Phillips B, et al, *Recent Advances in Medical Thermology*, New York: Plenum Press, 1984:5-15.
- 10.) Uematsu S. *Symmetry of Skin Temperature Comparing One Side of the Body to the Other*. *Thermology* 1985;1:4-7.
- 11.) Amalu, W., Tiscareno, L., et al. *Precision Radiology: Module 1 and 5 -- Applied Upper Cervical Biomechanics Course*. International Upper Cervical Chiropractic Association, 1993.
- 12.) Amalu, W., Tiscareno, L., et al. *Precision Multivector Adjusting: Module 3 and 7 -- Applied Upper Cervical Biomechanics Course*. International Upper Cervical Chiropractic Association, 1993.
- 13.) Gardner, E. *Pathways to the Cerebral Cortex for Nerve Impulses from Joints*. *Acta Anat* 1969;56:203-216.
- 14.) Wyke, B. *The Neurology of Joints: A Review of General Principles*. *Clin Rheum Dis* 1981;7:223-239.
- 15.) Coote, J. *Somatic Sources of Afferent Input as Factors in Aberrant Autonomic, Sensory, and Motor Function*. In: Korr, I., ed. *The Neurobiologic Mechanisms in Manipulative Therapy*. New York: Plenum, 1978:91-127.

- 16.) Denslow, J., Korr, I., Krems, A. *Quantitative Studies of Chronic Facilitation in Human Motorneuron Pools*. Am J Physiol 1987;150:229-238
- 17.) Korr, I. *Proprioceptors and the Behavior of Lesioned Segments*. In: Stark, E. ed. *Osteopathic Medicine*. Acton, Mass.: Publication Sciences Group, 1975:183-199.
- 18.) Heiss, W., Hayakawa, T., Waltz, A., *Cortical Neuronal Function During Ischemia*. Arch Neurol 1976;33:813-20
- 19.) Astrup, J., Siesjo, B., Symon, L. *Thresholds in Cerebral Ischemia -- The Ischemic Penumbra*. Stroke 1981;12:723-5
- 20.) Roski, R., Spetzler, R., Owen, M., et al. *Reversal of Seven Year Old Visual Field Defect with Extracranial-Intracranial Anastomosis*. Surg Neurol 1978;10:267-8
- 21.) Mathew, R., Meyer, J., et al. *Cerebral Blood Flow in Depression*. Lancet 1980;1(818):1308
- 22.) Mathew, R., Weinmann, M., Barr, D. *Personality and Regional Cerebral Blood Flow*. Br J Psychiatry 1984;144:529-32
- 23.) Jacques, S. Garner, J. *Reversal of Aphasia with Superficial Temporal Artery to Middle Cerebral Artery Anastomosis*. Surg Neurol 1976;5:143-5
- 24.) Lee, M., Ausman, J., et al. *Superficial Temporal to Middle Cerebral Artery Anastomosis. Clinical Outcome in Patients with Ischemia of Infarction in Internal Carotid Artery Distribution*. Arch Neurol 1979;36:1-4
- 25.) DeBoer, K., Harmon, R., et al. *Inter- and Intra-examiner Reliability of Leg Length Differential Measurement: A Preliminary Study*. J Manipulative Physiol Therap 1983;6:61-66
- 26.) Falltrick, D., Pierson, S. *Precise Measurement of Functional Leg Length Inequality and Changes Due To Cervical Spine Rotation in Pain-Free Students*. J Manipulative Physiol Therap 1989;12:364-368
- 27.) Keating, J. *Inter-examiner Reliability of Motion Palpation of the Lumbar Spine: A Review of Quantitative Literature*. Am J Chiro Med 1989;2:107-110
- 28.) Nansel, D., Peneff, A., Jansen, R., et al. *Interexaminer Concordance in Detecting Joint-Play Asymmetries in the Cervical Spines of Otherwise Asymptomatic Subjects*. J Manipulative Physiol Therap 1989;12:428-433